

DEMENTIA WITH LEWY BODIES
by Bradley Boeve, MD

The article that you are viewing on the Lewy Body Dementia Association (LBDA) website was authored by Bradley Boeve, MD and published by the American Academy of Neurology (AAN). We would like to thank the AAN for granting their permission to include this article on the LBDA website. It is a good reference tool for families, caregivers and medical professionals, in understanding, diagnosing and treating LBD. Please attach this acknowledgment page to all printed and distributed copies of the article.

Acknowledgment

Reprinted with permission from Bradley BF. Dementia with Lewy bodies. In: Dementia. Continuum: Lifelong Learning in Neurology 2004;10(1):81-112. Copyright (c) 2004, AAN Enterprises, Inc.

Article Contents

1. Terms associated with DLB and LBD
2. Most informative studies in the diagnostic work-up of suspected DLB
3. Neuropsychological, electrophysiologic and radiologic characteristics of DLB
4. Features and disorders that may precede the development of DLB
5. Key management strategies most likely to improve symptomatology in DLB patients
6. Some controversies and uncertainties in DLB phenomenology.

Lewy Body Dementia Association, Inc.
PO Box 451429, Atlanta, GA 31145-9429
+1.404.935.6444 (office) +1.480.422.5434 (fax)
Website: www.lewybodydementia.org
Caregiver Helpline: +1.800.539.9767

DEMENTIA WITH LEWY BODIES

Bradley F. Boeve

ABSTRACT

The diagnosis and management of patients with dementia with Lewy bodies (DLB) are challenging. This chapter will (1) review the terms and nomenclature associated with DLB and Lewy body disease (LBD), (2) review which studies are most informative in the diagnostic workup of suspected DLB, (3) review the clinical, neuropsychologic, electrophysiologic, and radiologic features characteristic of DLB, (4) review the spectrum of features and disorders that can precede the development of DLB, (5) review the key management strategies most likely to improve symptomatology in patients with DLB, and (6) discuss some of the controversies and uncertainties in DLB phenomenology.

OVERVIEW

In 1961, Okazaki and colleagues first described Lewy bodies in the cerebral cortex in patients with dementia (Okazaki et al, 1961). Lewy bodies are difficult to identify when viewing standard hematoxylin- and eosin-stained cortical regions, perhaps explaining why so few additional reports occurred over the following two decades. With the application of ubiquitin immunohistochemical techniques in the 1980s, Lewy bodies in the cortical and subcortical regions were easier to identify. In the late 1990s, soon after mutations in the α -synuclein gene were found in two kindreds with familial parkinsonism associated with Lewy body disease, α -synuclein immunocytochemistry was developed and applied to autopsied brain tissue, and Lewy bodies and Lewy neurites stained intensely (Spillantini et al, 1998). Neuropathologists can now identify extranigral Lewy bodies with relative ease (Dickson, 2002; Kosaka, 2000).

Several terms have been used when describing patients with known or suspected Lewy body pathology. These

include Lewy body disease, Lewy body dementia, the Lewy body variant of Alzheimer's disease (AD), diffuse Lewy body disease, cortical Lewy body disease, and senile dementia of the Lewy type. The Consortium on Dementia with Lewy bodies (CDLB) developed consensus criteria for the clinical and neuropathologic diagnoses of what is now termed dementia with Lewy bodies (DLB) (McKeith et al, 1996). Since the contribution of Alzheimer's pathology to the clinical features in DLB is not clear, the presence of the Alzheimer's pathology does not exclude the diagnosis of DLB. Based primarily on cases in hospital-based and referral-based samples, the frequency of DLB is approximately 15% to 25% of cases with irreversible dementia (McKeith et al, 1996). Controversy continues as to whether patients with typical features of Parkinson's disease (PD) who subsequently develop dementia (ie, Parkinson's disease with dementia [PDD]) have the same underlying pathophysiologic process as do patients with dementia, fluctuations, and visual hallucinations who subsequently develop

KEY POINTS:

- A Lewy bodies are difficult to identify when viewing standard hematoxylin- and eosin-stained cortical regions. With the advent of α -synuclein immunocytochemistry applied to autopsied brain tissue, Lewy bodies and Lewy neurites stain intensely, and neuropathologists can now identify extranigral Lewy bodies with relative ease.
- A Several terms have been used when describing patients with known or suspected Lewy body pathology: Lewy body disease, Lewy body dementia, the Lewy body variant of Alzheimer's disease, diffuse Lewy body disease, cortical Lewy body disease, and senile dementia of the Lewy type.

KEY POINTS:

- A** One useful approach to systematically characterize symptomatology and to decide on management is to view features in each of five categories: cognitive impairment, neuropsychiatric features, motor dysfunction, sleep disorders, and autonomic dysfunction.
- A** Fluctuations are considered a defining feature of DLB; this phenomenon refers to periods of time when cognition and arousal are near normal that are in contrast to other periods of more marked confusion or hypersomnolence.
- A** Another defining feature of DLB is the presence of visual hallucinations, which are often vivid and well-formed false perceptions of insects, animals, or people.

parkinsonism (ie, DLB), differing primarily in the time course of when the various features became manifest. In this monograph, we will view DLB and PDD as clinical syndromes and reserve the term Lewy body disease (LBD) for the histopathologic disorder. Terms and definitions pertinent to DLB are described in Box 4-1.

CLINICAL FEATURES

A wide variety of symptoms and signs can occur in DLB (Ballard et al, 1999; Ballard et al, 2001; Boeve et al, 2003c; Boeve et al, 1998; Galasko, 2001; Hishikawa et al, 2003; McKeith et al, 2003) (Table 4-1). The time course of the appearance of certain features also tends to vary, making counseling patients and families about future symptoms challenging. One useful approach to systematically characterize symptomatology and to decide on management is to view features in each of five categories: cognitive impairment, neuropsychiatric features, motor dysfunction, sleep disorders, and autonomic dysfunction (Case 4-1).

Cognitive Impairment

Memory impairment can vary from slight to very severe (Simard et al, 2000). Many individuals experience executive dysfunction, with difficulties understanding complex or multistep instructions, solving problems, and reasoning (Simard et al, 2000). Many others experience what some term verbal blocking, in which one tends to lose one's train of thought in the middle of a sentence or conversation. Apathy and bradyphrenia are common. Many also note problems with vision, but no or only minor abnormalities are found when examined by ophthalmologists. Spatial or geographic disorientation can occur, in which patients get lost while driving, have difficulties navigating in shopping centers

or malls or even their own homes. Visuospatial impairment is often easily demonstrated in the office (eg, intersecting pentagons on the Mini-Mental State Examination [Ala et al, 2001]) and on more detailed neuropsychological tests (Mori et al, 2000). Misidentification errors involving people can occur and are particularly upsetting when patients fail to recognize their own spouse or children. Some believe their own reflections in mirrors are someone other than themselves, sometimes leading to conversations or arguments with the perceived individual. Some of these cognitive features are thought to result from reduced cholinergic activity, while others are likely due to dopaminergic dysfunction.

Fluctuations are considered a defining feature of DLB (McKeith et al, 1996; McKeith et al, 1999); this phenomenon refers to periods of time when cognition and arousal are near normal that are in contrast to other periods of more marked confusion or hypersomnolence. Although fluctuations have been difficult to operationalize and measure, tools now exist that differentiate fluctuations associated with DLB from those with other disorders (Walker et al, 2000a; Walker et al, 2000b). However, the methods for measuring fluctuations have not made their way into routine clinical practice. Whether fluctuations represent neurochemical alterations, one or more sleep disorders, or some combination of these remains to be elucidated.

Neuropsychiatric Features

Another defining feature of DLB is the presence of visual hallucinations (McKeith et al, 1996; McKeith et al, 1999). These hallucinations are often vivid and well-formed false perceptions of insects, animals, or people (Aarsland et al, 2001). The hallucinations can be in black and white or in color, and at times they are frightening. Some

Box 4-1

TERMS

- " Amnesia: forgetfulness for details of recent events and conversations and upcoming appointments
- " Anxiety: feelings of anxiousness that affect everyday functioning
- " Apathy: lack of motivation to initiate conversations or perform activities
- " Auditory hallucinations: perception that sounds or voices are audible when none are actually present
- " Bradykinesia: slowness of movement
- " Bradyphrenia: slowness of thought
- " Capgras syndrome: belief that a spouse has been replaced by a similar-appearing imposter
- " Delusions: sustained false belief that something is true when it is not actually the case
- " Depression: loss of interests, feelings of helplessness and hopelessness, poor appetite, weight loss, awakening after midnight and struggling to fall back to sleep
- " Excessive daytime somnolence: tendency to fall asleep intermittently during the day
- " Executive dysfunction: problems in reasoning, problem solving, judgment, etc
- " Fluctuations: fluctuating arousal and/or cognition, with some hours or days appearing normal or near normal fluctuating with periods of much more severe sleepiness, confusion, disorientation, forgetfulness, etc
- " Illusions: perception that objects appear differently than is actually the case
- " Impotence: inability to achieve and maintain an erection
- " Masked facies: loss of facial expressions
- " Olfactory hallucinations: perception that odors are appreciated when none are present
- " Orthostatic hypotension: low blood pressure associated with lightheadedness and dizziness that occurs upon standing from a seated or lying position
- " Rapid eye movement (REM) sleep behavior disorder (RBD): parasomnia in which violent dreams and dream enactment behavior occurs; tendency to act out dreams
- " Rigidity: increased muscle tone in neck, arms, or legs
- " Spatial or geographic disorientation: difficulty navigating in familiar surroundings
- " Tactile hallucinations: perception that insects or animals are crawling on skin when none are present
- " Tremor: rhythmic oscillations of body parts, often involving the fingers, arms, or legs
- " Verbal blocking: difficulty expressing full sentences, losing track of one's thoughts, etc
- " Visual hallucinations: perception that objects, insects, animals, or people are seen when none are actually present
- " Visual misidentification: the belief that a familiar face, animal, or object is someone or something different than is actually the case
- " Visuo-perceptual/visuospatial dysfunction: difficulty perceiving and/or drawing complex images

patients talk to the perceived people or animals, or attempt to shoo them away. Arguments often ensue when family members attempt to convince patients that the images are not actually there. Many patients recognize

TABLE 4-1 Clinical Features Often Present in Dementia With Lewy Bodies

- " Cognitive Impairment
 - Varying degrees of memory impairment
 - Verbal blocking
 - Executive dysfunction
 - Bradyphrenia
 - Spatial/geographic disorientation
 - Visual misidentification
 - Fluctuations
- " Neuropsychiatric Features
 - Visual hallucinations
 - Illusions
 - Delusions
 - Capgras syndrome
 - Depression
 - Anxiety
 - Auditory, tactile, or olfactory hallucinations
 - Agitation or aggressive behavior (usually late in the course if present at all)
- " Motor Dysfunction
 - Tremor (often postural and symmetric)
 - Bradykinesia
 - Rigidity
 - Shuffling gait
 - Stooped posture
 - Difficulty with fine motor skills
 - Masked facies
- " Sleep Disorders
 - REM sleep behavior disorder (RBD)
 - Excessive daytime somnolence (EDS)

TABLE 4-1 Continued

- Insomnia
- Obstructive sleep apnea (OSA)
- Central sleep apnea (CSA)
- Restless legs syndrome (RLS)
- Periodic limb movements in sleep (PLMS)
- " Autonomic Dysfunction
 - Orthostatic hypotension
 - Impotence
 - Urinary incontinence
 - Constipation

that the visual experiences are, in fact, hallucinations and not actually present and manage to carry out their daily activities relatively undisturbed. Visual illusions, in which objects are perceived as something different than they actually are, can also occur. Some typical examples include perceiving chairs, lamps, or mailboxes as people or animals. Delusions are also frequent and typically have a paranoid quality (eg, beliefs that one's belongings have been stolen or that other people are invading or living in the home) (Aarsland et al, 2001). One particular delusion can evolve around misidentification errors, in which one believes that his or her spouse has been replaced by an identical-appearing imposter (Capgras syndrome) (Marantz and Verghese, 2002). Depression is very common in DLB (Aarsland et al, 2001; McKeith et al, 1996). Anxiety is also common. Auditory, tactile, or olfactory hallucinations are uncommon. Agitation or aggressive behavior tends to occur late in the illness if at all.

The underlying causes for these various features are not fully understood, but dopamine dysfunction is likely involved in hallucinations, delusions,

Case 4-1

A right-handed male physician began exhibiting cognitive, language, and gait difficulties at age 72. His difficulties with dictating notes, counseling patients, and writing prescriptions led to his retirement at age 73. He had great difficulties expressing his thoughts, often forgetting what he was saying midsentence when discussing various topics. He was forgetful for recent events and details of conversations, could not do calculations in his head, and made incorrect turns while driving. His thought processes were slower, as was his walking. His insight into his symptoms was remarkably keen. He stated that he had developed dressing apraxia. His symptoms began insidiously, and although they were progressive over time, his wife noted that his functional abilities fluctuated, and some hours or days were far better than others.

His past medical history was notable for alcohol abuse in the distant past and long-standing depression for which medical therapy was moderately effective. His sister and maternal uncle developed dementia in their late sixties. Pertinent positives on his review of symptoms were impotence for the past 10 years and, more recently, lightheadedness and near-syncopal episodes upon standing.

Initial neurologic examination at age 73 revealed a score of 25 out of 30 on the Mini-Mental State Examination (Folstein et al, 1975), with particularly poor performance on the intersecting pentagons. There was no evidence of apraxia or aphasia. Blood pressure was 170/102 mm Hg while sitting and 118/82 mm Hg while standing. There was limitation of upgaze on extraocular movement testing, subtle hypomimia, mildly decreased alternating motion rates of the fingers and hands, and a mild symmetric postural tremor. The remainder of his examination was within normal limits.

All laboratory studies for treatable causes of cognitive impairment were negative or normal.

Electroencephalography showed moderately severe dysrhythmia and delta slowing. Neuropsychometric testing showed impairment in verbal fluency, cognitive flexibility, and visuospatial functioning, yet preserved general intelligence, confrontation naming, and memory.

Representative coronal magnetic resonance (MR) images are shown in Figure 4-1.

On further questioning, his wife noted that beginning 9 years ago, he exhibited nocturnal behaviors in which he yelled, cursed, vigorously shook limbs, etc, as if he were "acting out his dreams." When awakened, he often described being chased or attacked by people or animals.

Polysomnography showed increased electromyographic tone and two brief episodes of vigorous shaking movements in one hand during rapid eye movement (REM) sleep, thus demonstrating the typical electrophysiologic and behavioral manifestations of REM sleep behavior disorder (RBD). No epileptiform activity was present. He also had evidence of moderate obstructive sleep apnea, for which nasal continuous positive airway pressure (CPAP) therapy was prescribed. His RBD was considered mild enough that pharmacotherapy was not deemed necessary. Nasal CPAP resulted in significant improvement in his alertness, concentration, mood, and psychomotor speed.

Donepezil was prescribed with further improvement in his verbal blocking, apathy, concentration, and mood. Carbidopa/levodopa was subsequently added, and his parkinsonian symptoms and signs improved.

Months later he traveled with his wife for a vacation in the tropics. For unclear reasons, he developed visual hallucinations and delusions shortly after checking into the hotel.

He was brought to the local hospital emergency department, and although the family pleaded with the medical staff not to administer haloperidol to manage his

Continued from page 85

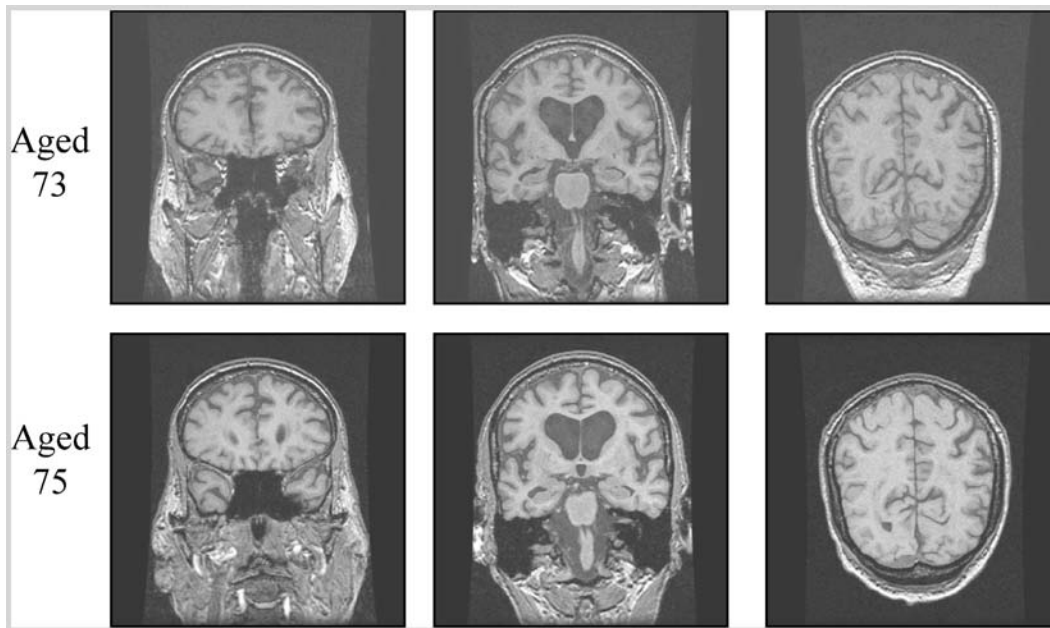


FIGURE 4-1 Coronal T1-weighted magnetic resonance images of Case 4-1 at ages 73 (top row) and 75 (bottom row). Note the minimal cerebral cortical and hippocampal atrophy and lack of significant progressive atrophy on these images. Although there is mild ventricular enlargement, there is no evidence of transependymal flow on T2-weighted images (not shown) to suggest normal pressure hydrocephalus.

escalating psychosis and agitation, 2 mg were given intramuscularly, and he was admitted. Shortly thereafter he developed marked encephalopathy, hypersomnolence, and generalized rigidity. He was transferred to another institution, and with gradual titration of quetiapine, his cognition and psychosis improved over a period of weeks, although moderate rigidity persisted.

Over the subsequent 2 years, his cognitive, neuropsychiatric, and motor difficulties changed minimally. At one point he stated, "I clearly meet criteria for dementia, but my psychosis and depression have remained in check. My orthostatism is my most troubling issue now." Representative coronal MR images, performed 2 years after the initial scan, are shown in Figure 4-1.

Comment. This case illustrates several key concepts in DLB phenomenology, including: (1) many of the clinical, neuropsychological, electrophysiologic, and radiologic features are qualitatively different from those associated with typical AD; (2) the clinical features of DLB are often preceded by RBD by years or decades; (3) other features such as depression and autonomic dysfunction may precede the development of cognitive impairment and parkinsonism; (4) conventional neuroleptics should be avoided in patients with DLB; (5) insight is often relatively preserved in DLB patients; and (6) some DLB patients can enjoy a reasonable quality of life for many years with a comprehensive approach toward management.

and agitation, and serotonin dysfunction is likely involved in depression and anxiety. REM sleep/wakefulness dysregulation has also been proposed as a mechanism underlying visual hallucinations, based on polysomnographic monitoring in patients with PD and psychosis, in which the dream imagery of REM sleep may invade into wakefulness (Arnulf et al, 2000). A similar mechanism has been proposed to underlie hallucinations associated with DLB (Boeve et al, 2003a; Boeve et al, 2001b). If further studies substantiate this mechanism, treatments already known to be efficacious in the management of narcolepsy may prove useful in the management of hallucinations, hypersomnolence, etc associated with DLB (Boeve et al, 2003a; Boeve et al, 2001a).

Motor Dysfunction

Spontaneous parkinsonism (ie, unrelated to dopamine antagonist exposure) is also a defining characteristic of DLB (McKeith et al, 1996; McKeith et al, 1999). Signs and symptoms include masked facies, stooped posture, shuffling gait, bradykinesia, difficulty with fine motor skills (such as tying shoes and buttoning), sialorrhea, and tremor (Del Ser et al, 2000). While some patients have a unilateral or asymmetric rest tremor with a “pill-rolling” quality that is typical of PD, many have a mild-to-moderate postural tremor that is often symmetric. Myoclonus occurs in some patients, which can complicate differentiation from Creutzfeldt-Jakob disease if progression occurs over a short period of time. Many of these symptoms and signs result from reduced dopaminergic activity.

Sleep Disorders

RBD is common in DLB (as well as in PD and multiple system atrophy)

(Boeve et al, 2003a; Boeve et al, 2001b; Boeve et al, 2003c; Boeve et al, 1998; Ferman et al, 2002; Ferman et al, 1999). Affected patients seem to act out their dreams by yelling, screaming, punching, kicking, swinging, jumping out of bed, etc (Boeve et al, 2003a; Olson et al, 2000; Schenck and Mahowald, 2002) (Table 4-2). The dreams often have a chasing or attacking theme, with the patient attempting to protect himself or herself. When the patient is awakened, the description of the dream tends to match the behaviors that were exhibited. Injuries to patients and their bed partners can occur. RBD often begins years or even decades before any cognitive or motor symptoms develop, and therefore RBD may be the first sign of an evolving neurodegenerative disorder in some individuals. Many DLB patients also have excessive daytime somnolence, in which they struggle to stay awake through the day (Boeve et al, 2001a). Other sleep disorders in DLB include insomnia, obstructive sleep apnea (OSA), central sleep apnea, restless legs syndrome, and periodic limb movement in sleep (Boeve et al, 2001a). All of these sleep disorders are important to recognize as treatments exist for each one.

RBD is intriguing as it tends to occur in certain disorders (eg, DLB, PD, and multiple system atrophy) but not in others (eg, AD, Pick’s disease, frontotemporal dementia, corticobasal degeneration) (Boeve et al, 2003a; Boeve et al, 2001b; Boeve et al, 2003c). Dysfunction in brain stem neuronal networks are believed to underlie RBD (Boeve et al, 2003a; Boeve et al, 2003c).

Autonomic Dysfunction

Orthostatic hypotension, impotence, urinary incontinence, and constipation are common in DLB (Ballard et al, 1998; Hishikawa et al, 2003; Pakiam

KEY POINTS:

A Spontaneous parkinsonism (ie, unrelated to dopamine antagonist exposure) is also a defining characteristic of DLB. Signs and symptoms include masked facies, stooped posture, shuffling gait, bradykinesia, difficulty with fine motor skills, sialorrhea, and tremor.

A REM sleep behavior disorder is common in DLB, in which affected patients seem to act out their dreams by yelling, screaming, punching, kicking, swinging, jumping out of bed, etc.

A Orthostatic hypotension, impotence, urinary incontinence, and constipation are common in DLB.

KEY POINTS:

- A** Recent clinicopathologic analyses have shown that the accuracy of the clinical criteria for DLB has varied widely among groups of investigators.
- A** According to the current DLB criteria, the diagnosis of DLB is appropriate for those who have visual hallucinations and/or fluctuations and develop parkinsonism (1) at any point after the onset of dementia, or (2) no more than 1 year before the onset of dementia; the term PDD is appropriate for those who develop dementia more than 1 year after the onset of parkinsonism.

TABLE 4-2 Typical Clinical Features of Rapid Eye Movement Sleep Behavior Disorder (RBD)

- " Male gender predilection
- " Onset age 50 to 65 years (range 20 to 80 years)
- " Vocalizations, swearing, screaming
- " Motor activity varies from simple limb jerks to complex motor behavior, with injuries to patient or bed partner
- " Dreams often involve chases or attacks by animals or humans
- " Exhibited behaviors mirror dream content
- " Behaviors tend to occur in latter half of the sleep period
- " When associated with neurodegenerative disease, RBD often precedes dementia and/or parkinsonism by years or decades

Reprinted with permission from Boeve B, Silber M, Ferman T, et al. REM sleep behavior disorder in Parkinson's disease, dementia with Lewy bodies, and multiple system atrophy. In: Bedard M, Agid Y, Chouinard S, et al, editors. Mental and behavioral dysfunction in movement disorders. Totowa, NJ: Humana Press, 2003a:383–397.

et al, 1999), although the frequency of each feature in DLB has not been systematically studied. Lewy bodies have been found in the intermediolateral column of the spinal cord, reflecting the rather widespread nature of Lewy body pathology in the central nervous system (Hishikawa et al, 2003; Pakiam et al, 1999).

DIAGNOSTIC CRITERIA

The criteria for the clinical diagnosis of DLB as per the CDLB (or McKeith) criteria, originally published in 1996 (McKeith et al, 1996), were refined in 1999 (McKeith et al, 1999); the clinical and pathologic criteria are shown in Tables 4-3 and 4-4, respectively. A similar set of clinical criteria, proposed by the Consortium to Establish a Registry in Alzheimer's Disease (Mirra, 1994), is shown in Table 4-5. Recent clinicopathologic analyses have shown that the accuracy of the clinical criteria has varied widely among groups of investigators (Hohl et al, 2000; Lopez et al, 2000; McKeith et al, 2000b; Mega et al, 1996; Verghe

et al, 1999). Although the specificity for the CDLB criteria is rather high in most studies, sensitivity is relatively low, and further refinement in the criteria is necessary.

One criticism of the CDLB criteria is the lack of details regarding the minimum number and specific extrapyramidal features that should warrant the label of parkinsonism. Also, according to the CDLB criteria, the diagnosis of DLB cannot be applied to those who develop dementia greater than 1 year after the onset of parkinsonism. In other words, the diagnosis of DLB is appropriate for those who have visual hallucinations and/or fluctuations and develop parkinsonism (1) at any point after the onset of dementia, or (2) no more than 1 year before the onset of dementia; the term PDD is appropriate for those who develop dementia more than 1 year after the onset of parkinsonism. Another criticism is the lack of operational criteria for the determination of whether "fluctuations" are present. Some investigators have suggested that RBD should be added as a core criterion for the diagnosis of DLB

TABLE 4-3 Clinical Diagnosis of Dementia With Lewy Bodies (DLB): Consortium on Dementia With Lewy Bodies (CDLB) or “McKeith” Criteria

- " Core Features
 - Progressive cognitive decline that interferes with normal social and occupational functioning
 - Deficits on tests of attention/concentration, verbal fluency, psychomotor speed, and visuospatial functioning often prominent
 - Prominent or persistent memory impairment may not be present early in course of illness
 - Two of the following core features necessary for the diagnosis of clinically probable DLB, and one necessary for the diagnosis of clinically possible DLB:
 - Fluctuating cognition or alertness
 - Recurrent visual hallucinations
 - Spontaneous features of parkinsonism
- " Supportive Features
 - Repeated falls
 - Syncope
 - Transient loss of consciousness
 - Neuroleptic sensitivity
 - Systematized delusions
 - Tactile or olfactory hallucinations
 - REM sleep behavior disorder
 - Depression
- " Features Suggesting Disorder Other Than DLB
 - Cerebrovascular disease evidenced by focal neurologic signs and/or cerebral infarct(s) present on neuroimaging study
 - Findings on examination or on ancillary testing that another medical, neurologic, or psychiatric disorder sufficiently accounts for clinical features

REM = rapid eye movement.

Adapted with permission from McKeith IG, Galasko D, Kosaka K, et al. Consensus guidelines for the clinical and pathological diagnosis of dementia with Lewy bodies: report of the CDLB international workshop. *Neurology* 1996;47:1113–1124; and McKeith IG, Perry EK, Perry RH, et al. Report of the second dementia with Lewy bodies international workshop: diagnosis and treatment. *Neurology* 1999;53:902–905. Copyright # 1996,1999, AAN Enterprises, Inc.

(Boeve et al, 2003c; Knopman et al, 2003). The timing of the onset of visual hallucinations may also be important, as patients with DLB tend to experience visual hallucinations early in the

disease course, whereas patients with AD tend to experience them late in the disease course. These and other issues will surely be debated at future consensus conferences.

KEY POINT:

A No specific findings on blood, urine, or CSF analysis that are diagnostic of DLB have been identified as yet.

TABLE 4-4 Pathologic Diagnosis of Dementia With Lewy Bodies (DLB): Consortium on Dementia With Lewy Bodies (CDLB) Or "McKeith" Criteria

- " Essential for Diagnosis of DLB
Lewy bodies
- " Associated but not Essential
Lewy-related neurites
Plaques
Neurofibrillary tangles
Regional neuronal loss, especially brain stem and nucleus basalis of Meynert
Spongiform change and synapses loss
Neurochemical abnormalities and neurotransmitter deficits

Adapted with permission from McKeith IG, Galasko D, Kosaka K, et al. Consensus guidelines for the clinical and pathological diagnosis of dementia with Lewy bodies: report of the CDLB international workshop. *Neurology* 1996;47:1113–1124. Copyright # 1996, AAN Enterprises, Inc.

TABLE 4-5 Clinical Diagnosis of Dementia With Lewy Bodies (DLB): Consortium to Establish a Registry for Alzheimer's Disease (CERAD) Criteria

- " Core Features
Clinical Dementia Rating score of 0.5 to 2.0
Two of the following:
Delusions or hallucinations
Extrapyramidal signs
Unexplained falls/change of consciousness
- " Supportive Features
Fluctuating course
Levodopa failure
Dementia > extrapyramidal signs
Weight loss, dysphagia, decreased mood

Reprinted with permission from Mirra S, Gearing M, Heyman A. CERAD guide to the clinical assessment of Alzheimer's disease and other dementias. CERAD, 1994. (For information, contact Albert Heyman, MD, Box 3203, Duke University Medical Center, Durham, NC 27710.)

DIAGNOSTIC EVALUATION

Laboratory testing, neuropsychological testing, and structural neuroimaging are recommended for evaluating individuals with dementia (Knopman et al, 2001) (Appendix B). Although other diagnostic procedures such as electroencephalography (EEG) and positron emission tomography are not recommended in the routine workup of individuals with cognitive impairment/dementia, these procedures may be helpful in select patients (Table 4-6). The following discussion presents data published to date on the findings associated with DLB.

Blood and Urine

No specific findings on laboratory testing of blood or urine have yet been identified that are characteristic of DLB. The role of laboratory testing is most helpful in identifying treatable causes of cognitive impairment (Knopman et al, 2001).

TABLE 4-6 Findings on Ancillary Testing Favoring Underlying Lewy Body Disease Rather Than Alzheimer's Disease in the Setting of Dementia

- " Neuropsychological testing: impairment on measures of attention, visual-perceptual organization, and letter fluency, with relative preservation on measures of confrontation naming and verbal memory
- " Electroencephalography: moderate to severe delta or dysrhythmic slowing
- " Magnetic resonance imaging: minimal neocortical and hippocampal atrophy
- " Single-photon emission computed tomography or positron emission tomography: hypoperfusion/hypometabolism most prominent in the parieto-occipital regions
- " Polysomnography: increased electromyographic tone associated with dream enactment behavior during rapid eye movement sleep

Cerebrospinal Fluid Analysis

No specific findings on cerebrospinal fluid (CSF) analysis that are diagnostic of DLB have been identified as yet.

Neuropsychological Testing

Neuropsychological testing typically shows impairment on measures of attention/concentration and visuospatial functioning in DLB (Mori et al, 2000; Salmon et al, 1996; Simard et al, 2000). A similar pattern of deficits on neuropsychological testing occurs in patients with dementia plus RBD, in which impaired visual-perceptual organizational skills, constructional praxis, and verbal fluency have been demonstrated (Boeve et al, 1998). A subsequent analysis in which the neuropsychometric profile of patients with dementia plus RBD was compared with cases of autopsy-proven AD revealed a striking double dissociation, in which the dementia plus RBD group had worse impairment on measures of attention, visual-perceptual organization, and letter fluency, while the AD group had significantly worse performance on confrontation naming and verbal

memory (Ferman et al, 1999). The findings indicated that patients with RBD and degenerative dementia have a significantly different pattern of cognitive performance from AD, and the pattern of cognitive differences from AD is similar to that reported between DLB and AD (Ferman et al, 1999). The neuropsychometric features in patients with dementia and RBD who did not have parkinsonism or visual hallucinations were recently reported (Ferman et al, 2002). Neurocognitive data from groups of patients with a similar dementia severity were compared in those with clinically probable DLB, dementia and RBD without visual hallucinations or parkinsonism, and autopsy-proven AD. The neurocognitive profiles between the probable DLB and dementia with RBD groups did not differ, and when compared with the AD group, both had worse visual perceptual organization and sequencing and better confrontation naming and verbal memory. These findings demonstrated that patients with dementia and RBD who do not have parkinsonism or visual hallucinations have a dementia syndrome that is

KEY POINTS:

- A Neuro-psychological testing typically shows impairment on measures of attention/concentration and visuospatial functioning in DLB.
- A Patients with dementia and RBD who do not have parkinsonism or visual hallucinations have a dementia syndrome that is neuro-psychologically indistinguishable from that of probable DLB, and the features of both of these groups differ from AD. These findings suggest that the presentation of dementia and RBD despite the absence of the other core features of DLB may indicate underlying Lewy body disease.

KEY POINTS:

- A** Compared with patients with AD, patients with DLB tend to have more background slowing on electroencephalography less hippocampal atrophy on MRI, and occipital hypoperfusion/hypometabolism on functional neuroimaging studies.
- A** A polysomnogram can be justified for almost any patient with loud disruptive snoring and apneic pauses (and thus probable obstructive sleep apnea), hypersomnia associated with nocturnal leg jerks (and thus probable symptomatic periodic limb movements in sleep), or frequent dream enactment behavior (and thus the potential for injury due to RBD).

neuropsychologically indistinguishable from that of probable DLB, and the features of both of these groups differ from AD (Ferman et al, 2002). Therefore, in the absence of visual hallucinations or parkinsonism, the presentation of dementia and RBD may indicate underlying Lewy body disease. This study suggests that early detection of evolving DLB may be possible and emphasizes the utility of probing for RBD in the clinical interview and of neuropsychological testing. A recent report on the neuropathologic findings in patients with RBD plus dementia, in which all patients had limbic or neocortical Lewy body disease, emphasizes the RBD/Lewy body disease association and the very low (if not absent) frequency of RBD associated with pure AD (Boeve et al, 2003c).

Electroencephalography

Studies involving electroencephalography have shown more background slowing in patients with DLB compared with those with AD (Briell et al, 1999). Although background slowing is not specific for DLB, normal findings on electroencephalography may argue against underlying DLB.

Structural Neuroimaging

In the setting of dementia, structural neuroimaging with computed tomography (CT) or magnetic resonance imaging (MRI) has classically been used to rule out a tumor, abscess, hydrocephalus, etc. The presence and topography of atrophy may, however, provide diagnostic information. There is ample data on the significance of hippocampal atrophy in patients with mild cognitive impairment (MCI) and AD (Jack et al, 2000; Jack et al, 1999), which stands to reason as the brunt of pathology in AD is in the mesial temporal lobes. Less hippocampal atrophy is evident on CT and MRI scans in DLB when compared with AD and vascular

dementia (Barber et al, 2000; Barber et al, 1999).

Functional Neuroimaging

Parietal and, particularly, occipital hypoperfusion of single-photon emission computed tomography (SPECT) and hypometabolism on positron emission tomography have been associated with DLB (Lobotesis et al, 2001; Minoshima et al, 2001; Turner et al, 1997). In two studies comparing the occipital hypoperfusion/hypometabolism of DLB with findings in AD, the sensitivity was modest to high (64% to 90%) while the specificity was high (80% to 86%) (Lobotesis et al, 2001; Minoshima et al, 2001). Additional radiologic-pathologic correlations are necessary to clarify the role of functional neuroimaging in dementia assessment.

Polysomnography

Although RBD appears to be quite frequent in and relatively specific for DLB in the setting of dementia, the positive and negative predictive values of RBD for DLB compared to the non-DLB dementing disorders have not been systematically studied in a prospective unbiased manner. The critical polysomnography (PSG) finding in RBD involves the loss of the normal electromyographic atonia during REM sleep, also known as REM sleep without atonia (RSWA). RSWA therefore represents the electrophysiologic substrate for RBD, but the diagnosis of RBD requires (1) RSWA plus (2a) a history of dream enactment behavior or (2b) dream enactment behavior during REM sleep captured on the PSG (Mahowald and Schenck, 2000). Some individuals who have the PSG finding of RSWA do not exhibit abnormal behaviors on the PSG and do not have a history of nightmares and dream enactment behavior. Although some of these patients subsequently develop clinical RBD, it remains to be seen if RSWA distinguishes

DLB from non-DLB cases in the setting of dementia. At present, therefore, it is difficult to justify performing a PSG if the only question is whether the patient has the electrophysiologic finding of RSWA. However, PSG can be justified for almost any patient with loud disruptive snoring and apneic pauses (and thus probable obstructive sleep apnea), hypersomnia associated with nocturnal leg jerks (and thus probable symptomatic periodic limb movements in sleep), frequent dream enactment behavior (and thus the potential for injury due to RBD), etc. If sufficient REM sleep is present on the PSG regardless of the primary indication for the PSG, electromyographic tone and motoric behavior during REM sleep can be scrutinized, thereby providing a means to determine if RSWA and RBD are present.

Autonomic Testing

While autonomic dysfunction clearly occurs in some patients with DLB (Ballard et al, 1998; Hishikawa et al, 2003; Pakiam et al, 1999), the frequency and qualitative features of such dysfunction and the role of autonomic testing in the assessment of dementia will require further study.

MANAGEMENT

No therapy has yet been identified that significantly alters Lewy body disease pathophysiology. Management is therefore directed toward target symptoms. Although only a few double-blind placebo-controlled clinical trials have been carried out specifically in DLB patients, sufficient experience provides some suggestions for therapy. Importantly, although progressive neuronal death does occur in DLB, the severity appears to be less than that in Alzheimer's disease and frontotemporal dementia (Dickson, 2001; Dickson, 2002; Kosaka 2000), suggesting that

medical therapy may be as or more effective in DLB than in other dementing disorders (Case 4-2). The following approach addresses strategies for the five categories of symptomatology as described above (Table 4-8).

Cognitive Impairment

The cholinergic deficit in DLB is now well established. There are several reports that dramatic improvement in cognitive functioning as well as neuropsychiatric symptoms can occur when cholinesterase inhibitors are used in patients with DLB (Lanctot and Herrmann, 2000; McKeith et al, 2000a; McKeith et al, 2003). The currently available cholinesterase inhibitors include tacrine, donepezil, rivastigmine, and galantamine. Because of the need for laboratory monitoring when using tacrine, this agent is rarely used. Although in theory cholinergic stimulation should worsen parkinsonism, increased parkinsonism with the cholinesterase inhibitors occurs very infrequently (McKeith et al, 2000a; McKeith et al, 2003); thus clinicians should consider prescribing one of these agents for DLB patients who do not have a contraindication to its use. Other agents that may improve cognition, apathy, and psychomotor slowing include the psychostimulants, carbidopa/levodopa, and the dopamine agonists, presumably through their effects on the frontosubcortical neural networks mediating attention and executive functioning.

Management of fluctuations has been difficult, probably due to the many possible etiologic underpinnings. Visuospatial impairment tends to be more resistant to drug therapy. Misidentification errors are also difficult to treat, although arguments with one's reflection in a mirror can be remedied by covering mirrors in the home.

KEY POINTS:

- A Although progressive neuronal death does occur in DLB, the severity appears to be less than that in Alzheimer's disease and frontotemporal dementia, suggesting that medical therapy may be as or more effective in DLB than in other dementing disorders.
- A Although in theory cholinergic stimulation should worsen parkinsonism, increased parkinsonism with the cholinesterase inhibitors occurs very infrequently; thus clinicians should consider prescribing one of these agents for DLB patients who do not have a contraindication to its use.

Case 4-2

A right-handed retired executive with 18 years of formal education began experiencing changes in cognition, mood and perception, motor functioning, and sleep in his mid seventies. He could not recall details of recent events and conversations, and he occasionally forgot to take his medications. He got lost while driving and later had trouble navigating in his own home. He developed a tremor, stooped posture, and shuffling gait. He was no longer able to care for himself. He verbalized despondence and poor appetite, which improved minimally after treatment with various selective serotonin reuptake inhibitors (SSRIs), but he denied hopelessness and suicidal ideation. He occasionally saw children or animals in the home that were not there, and he expressed concern that the children were stealing from him and might harm him. There was no history of dream enactment behavior, but he was falling asleep intermittently during the day. There were mild fluctuations in his symptomatology. His family arranged nursing home placement.

On initial neurologic examination, there was evidence of cognitive impairment (Short Test of Mental Status [Kokmen et al, 1991] score of 21/38 with deficits particularly in attention, learning, calculations, constructional praxis, and recall), limited upgaze on eye movement testing, mild asymmetric rest tremor and moderate symmetric postural tremor, asymmetric rigidity and bradykinesia, and minimal postural instability. He was intermittently drowsy during the interview and examination and scored 14 on the Epworth Sleepiness Scale (normal <10) (Johns, 1991). He had a large base of tongue and reduced anterior-posterior diameter in his oropharynx. A comprehensive neurobehavioral evaluation was undertaken, with findings as shown in Table 4-7.

TABLE 4-7 Initial Clinical Features and Findings on Ancillary Testing in Case 4-2

"	Clinical Features
p	Cognitive impairment
p	Parkinsonism
p	Depression
p	Visual hallucinations
p	Paranoid delusions
p	Hypersomnolence
"	Neuropsychological Findings
p	Impaired global functioning (Dementia Rating Scale 100/144)
p	Impaired attention/concentration, verbal fluency, visuospatial functioning (see copy of Rey-Osterrieth Complex Figure—left image on Figure 4-2)
p	Relatively preserved confrontation naming and verbal memory
"	Electroencephalographic Findings
p	Moderate dysrhythmic slowing without epileptiform activity
"	Polysomnographic Findings
p	Moderate obstructive sleep apnea (apnea/hypopnea index of 37, normal <5); nasal continuous positive airway pressure effective at 7 cm H ₂ O
p	Moderate periodic limb movements in sleep (PLMs) (45 PLMs associated with arousal per hour)
p	Normal electromyographic atonia and no abnormal behaviors during rapid eye movement sleep
"	Radiologic Findings
p	Mild generalized cerebral cortical atrophy on magnetic resonance imaging
p	Minimal hippocampal atrophy

Continued from page 94

He was diagnosed with dementia with Lewy bodies, depression, moderate obstructive sleep apnea, and periodic limb movement disorder. He was initiated on continuous positive airway pressure (CPAP) at 7 cm H₂O and carbidopa/levodopa CR 25/100 two tablets before bedtime, and upon follow-up 1 month later he and his family noted marked improvement in his hypersomnolence (Epworth Sleepiness Scale 4), but only mild improvement in cognition. He was then treated with donepezil 5 mg by mouth every morning and later titrated on carbidopa/levodopa 25/100 up to two tablets by mouth 3 times a day. The hallucinations resolved and his mood improved. Over the subsequent 2 months, his cognitive and motor difficulties improved further enabling him to move into an assisted living residence, learn how to use a computer, and even enjoy some travel abroad with a companion.

Follow-up examination 1 year after the initial evaluation revealed a Short Test of Mental Status score of 32/38, no drowsiness, and no significant parkinsonism. On neuropsychological testing, he scored 137/144 on the Dementia Rating Scale and his drawing of the Rey-Osterrieth Complex Figure (Osterrieth, 1944) was

remarkably normal (Figure 4-2). He was maintained on his daily and nightly doses of carbidopa/levodopa, donepezil with breakfast daily, and nasal CPAP.

He continued to reside in an assisted living setting and traveled with a companion to several cities abroad.

Subsequent evaluations demonstrated stability in his cognition (Short Test of Mental Status 35/38 and Dementia Rating Scale 132/144 3 years after the initial evaluation) and only mild parkinsonism.

Comment. While this case certainly is not typical of all patients with DLB, this patient exemplifies the remarkable and

sustained improvement in functional status, cognition, neuropsychiatric features, parkinsonism, and sleep disorders when a comprehensive approach toward management is undertaken.

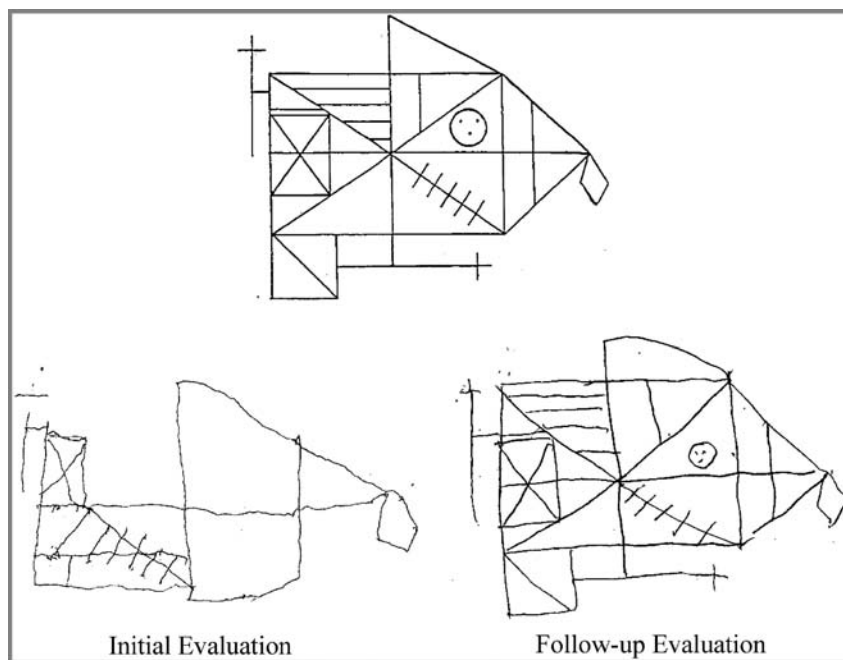


FIGURE 4-2

Drawings of the Rey-Osterrieth Complex Figure for Case 4-2 at the initial examination (left) and subsequent examination 1 year later (right). Note the marked distortion on the initial examination but essentially normal findings on the subsequent examination.

Neuropsychiatric Features

Visual hallucinations occur in most patients with DLB, but they do not require drug therapy in all patients.

Reassurance and redirection may be sufficient, particularly if the hallucinations are not frightening. In those patients who experience fright or

TABLE 4-8 Symptoms, Behaviors, and Disorders in Dementia With Lewy Bodies: Selected Medications With Suggested Dosing Schedules*

Symptom/ Behavior/Disorder	Medication	Starting Dose	Suggested Titrating Schedule	Typical Therapeutic Range
Cognitive Impairment				
Forgetfulness	Donepezil [‡]	5 mg qAM	Increase to 10 mg qAM 4 weeks later	5 mg qAM to 10 mg qAM
	Rivastigmine [‡]	1.5 mg bid	Increase in 1.5 mg increments for both doses every 2 to 4 weeks, maximum 6 mg bid	1.5 mg bid to 6.0 mg bid
	Galantamine [‡]	4 mg bid	Increase in 4 mg increments for both doses every 4 weeks, maximum 12 mg bid	4 mg bid to 12 mg bid
Apathy or psychomotor slowing or subcortical dementia	Methylphenidate [‡]	2.5 mg qAM	Increase in 2.5 mg to 5.0 mg increments q3 to 5 days in bid dosing (AM and noon)	5 mg qAM to 30 mg bid
	Amphetamine/dextroamphetamine [‡]	5 mg qAM	Increase in 5 mg increments q7 days in qd—bid (AM and noon) dosing, max 25 mg bid	5 mg qAM to 20 mg bid
	Modafinil [‡]	100 mg qAM	Increase in 100 mg increments each week, max 400 mg po qAM	100 mg qAM to 400 mg qAM
	Carbidopa/levodopa [‡]	25/100 1/2 tab tid	Increase in 1/2 tab increments over all 3 daily doses each week (take 1 hour before or after meals)	1 to 3 tabs tid
	Donepezil [‡]	5 mg qAM	Increase to 10 mg qAM 4 weeks later	5 mg qAM to 10 mg qAM
	Rivastigmine [‡]	1.5 mg bid	Increase in 1.5 mg increments for both doses every 2 to 4 weeks, maximum 6 mg bid	1.5 mg bid to 6.0 mg bid
	Galantamine [‡]	4 mg bid	Increase in 4 mg increments for both doses every 4 weeks, maximum 12 mg bid	4 mg bid to 12 mg bid

Continued on next page

TABLE 4-8 Continued

Symptom/ Behavior/Disorder	Medication	Starting Dose	Suggested Titrating Schedule	Typical Therapeutic Range
Neuropsychiatric Features				
Hallucinations or delusions or behavioral dyscontrol or agitation/aggression or nocturnal wandering or disinhibition	Donepezil [‡]	5 mg qAM	Increase to 10 mg qAM 4 weeks later	5 mg qAM to 10 mg qAM
	Rivastigmine [‡]	1.5 mg bid	Increase in 1.5-mg increments for both doses every 4 weeks, maximum 6 mg bid	1.5 mg bid to 6.0 mg bid
	Galantamine [‡]	4 mg bid	Increase in 4-mg increments for both doses every 4 weeks, maximum 12 mg bid	4 mg bid to 12 mg bid
	Risperidone [‡]	0.5 mg qhs	Increase in 0.5-mg increments q7 days in bid dosing (AM and hs)	0.5 mg qhs to 1.5 mg bid
	Olanzapine [‡]	2.5 mg qhs	Increase in 2.5-mg to 5-mg increments q7 days in bid dosing (AM and hs)	2.5 mg qhs to 10 mg bid
	Clozapine ^{††}	12.5 mg qhs	Increase in 12.5-mg increments q2 to 3 days	25 mg qhs to 50 mg tid
	Quetiapine [‡]	25 mg qhs	Increase in 25 mg increments q3 days	25 mg qhs to 100 mg qAM/ 400 mg qPM
	Valproic acid ^{†‡}	125 mg qhs	Increase in 125-mg increments q3 to 7 days in bid to tid dosing	250 mg qhs to 500 mg tid
Depression or emotional lability/ pseudobulbar affect	Carbamazepine ^{††}	100 mg qhs	Increase in 100-mg increments q3 to 7 days in bid to tid dosing	200 mg qhs to 200 mg tid
	Fluoxetine [§]	10 mg qd	Increase to 20 mg 2 to 4 weeks later	10 mg qd to 40 mg qd
	Sertraline [§]	25 mg qd	Increase to 50 mg 2 weeks later, titrate gradually up to max of 200 mg qd	50 mg qd to 100 mg qd
	Paroxetine [§]	10 mg qd	Increase to 20 mg 2 weeks later, titrate gradually up to max of 50 mg/d	10 mg to 40 mg qd
	Citalopram [§]	10 mg qd	Increase to 20 mg 2 weeks later, titrate gradually up to max of 60 mg/d	10 mg qd to 60 mg qd

Continued on next page

TABLE 4-8 Continued

Symptom/ Behavior/Disorder	Medication	Starting Dose	Suggested Titrating Schedule	Typical Therapeutic Range
Anxiety or obsessions/compulsions	Sertraline [§]	25 mg qd	Increase to 50 mg 2 weeks later, titrate gradually up to max of 200 mg qd	50 mg qd to 100 mg qd
	Paroxetine [§]	10 mg qd	Increase to 20 mg 2 weeks later, titrate gradually up to max of 50 mg/d	10 mg qd to 40 mg qd
	Buspirone [§]	5 mg bid	Increase in 5 mg increments in bid-tid dosing q3—5 days, max of 60 mg/d	5 mg tid to 10 mg tid
Motor Dysfunction				
Parkinsonism	Carbidopa/levodopa [§]	25/100 1/2 tab tid	Increase in 1/2 tab increments for all 3 daily doses each week (take 1 hour before or after meals)	1 to 3 tabs tid
	Pramipexole [§]	0.125 mg bid	Increase in 0.125 mg increments for both daily doses q2 to 3 days	0.25 mg bid to 1.0 mg bid
Sleep Disorders				
REM sleep behavior disorder	Clonazepam [‡]	0.25 mg qhs	Increase in 0.25 mg increments q7 days	0.25 mg/night to 1.0 mg/night
	Melatonin [‡]	3 mg qhs	Increase in 3-mg increments q3 to 5 days up to 12 mg if necessary	3 mg/night to 12 mg/night
Insomnia				
	Trazodone [‡]	25 mg qhs	Increase in 25-mg increments q3 to 5 days	50 mg/night to 200 mg/night
	Zolpidem	5 mg qhs	Increase up to 10 mg qhs	5 mg/night to 10 mg/night
	Quetiapine [‡]	12.5 mg qhs	Increase in 12.5-mg increments q3 to 5 days	12.5 mg/night to 100 mg/night
	Chloral hydrate [‡]	500 mg qhs	Increase in 500-mg increments q5 to 7 days	500 mg/night to 1500 mg/night
	Melatonin [‡]	3 mg qhs	Increase in 3-mg increments q3 to 5 days up to 12 mg if necessary	3 mg/night to 12 mg/night

Continued on next page

TABLE 4-8 Continued

Symptom/ Behavior/Disorder	Medication	Starting Dose	Suggested Titrating Schedule	Typical Therapeutic Range
Restless legs syndrome/ periodic limb movement disorder	Carbidopa/levodopa [‡]	25/100 or CR 25/100	1 tab qhs, increase to 2 tabs 1 week later if necessary	1 to 2 tabs qhs
	Pramipexole [‡]	0.125 mg qhs	Increase in 0.125 mg increments q2 to 3 days	0.25 mg/night to 0.75 mg/night
	Gabapentin [‡]	100 mg qhs	Increase in 100-mg increments q2 to 3 days	300 mg/night to 1200 mg/night
Excessive daytime somnolence	Methylphenidate [‡]	2.5 mg qAM	Increase in 2.5-mg to 5.0-mg increments q3 to 5 days in bid dosing (AM and noon)	5 mg qAM to 30 mg bid
	Amphetamine/ dextroamphetamine [‡]	5 mg qAM	Increase in 5-mg increments q7 days in qd—bid (AM and noon) dosing, max 25 mg bid	5 mg qAM to 20 mg bid
	Modafinil [‡]	100 mg qAM	Increase in 100-mg increments each week, max 400 mg po qAM	100 mg qAM to 400 mg qAM
Autonomic Dysfunction				
Orthostatic hypotension	Fludrocortisone	0.1 mg qd	Increase in 0.1-mg increments q5 to 7 days, max 1.0 mg/d	0.1 mg qd to 0.3 mg qd
	Midodrine	5 mg tid	Increase up to 10 mg tid if necessary	5 mg tid to 10 mg tid

qAM = every morning; bid = twice a day; po = by mouth; tid = three times a day; qhs = each bedtime, every night; q = every; hs = at bedtime; qd = every day; qPM = each evening.

*Disclaimer: The choice of which agents to use and which dosing schedules to recommend must be individualized. It is the responsibility of the clinician to consider potential side effects, drug interactions, allergic response, life-threatening reactions (eg, leukopenia with clozapine), dosing changes due to renal or hepatic dysfunction, etc, before administering any drug to any patient, including those listed above. Dr Boeve, Mayo Foundation, and the American Academy of Neurology will not be responsible for any adverse reactions of any kind to any patient regarding the content of this information.

[†]Periodic laboratory monitoring necessary—refer to guidelines provided by manufacturer.

[‡]Not FDA-approved for the symptoms/behavior/disorder.

[§]FDA-qualified.

Adapted with permission from Boeve BF. Diagnosis and management of the non-Alzheimer dementias. In: Noseworthy JW, ed. Neurological therapeutics: principles and practice. London: Martin Dunitz, 2003;2826–2854.

develop paranoid delusions around the hallucinations, drug therapy is often necessary. The cholinesterase inhibitors can be effective for hallucinations in any sensory sphere (Lanctot and Herrmann, 2000; McKeith et al,

2000a; McKeith et al, 2003). Neuroleptic sensitivity, in which striking and irreversible parkinsonism can evolve shortly after use of neuroleptics, has led to the recommendation that conventional neuroleptics should be

KEY POINTS:

- A The cholinesterase inhibitors can also decrease the frequency and severity of visual hallucinations and delusions.
- A The atypical neuroleptics are often effective for hallucinations, delusions, and agitation, and the selective serotonin reuptake inhibitors are often effective for depression. Conventional neuroleptics and tricyclic antidepressants should be avoided in patients with DLB.
- A Many of the parkinsonian signs and symptoms of DLB can respond to carbidopa/levodopa and the dopamine agonists. Their use is primarily limited by the side effects.
- A Orthostatic hypotension can be managed by liberalizing salt in the diet, salt tablets, thigh-high compression stockings, fludrocortisone, and midodrine.

avoided in patients with DLB (McKeith et al, 1996; McKeith et al, 2003). There are infrequent reports of neuroleptic sensitivity even among the newer atypical neuroleptic agents, and some of these have been minimally effective for psychotic features (Walker et al, 1999). Hallucinations, delusions, or agitation in patients with DLB as well as Parkinson's disease (with or without dementia) can improve with clozapine (Dewey and O'Suilleabhain, 2000), risperidone (Leopold, 2000), olanzapine (Aarsland et al, 1999; Cummings et al, 2002), and quetiapine (Dewey and O'Suilleabhain, 2000; Tariot and Ismail, 2002), as well as the cholinesterase inhibitors. Therefore, if problematic hallucinations, delusions, or agitation occur in patients with DLB who do not respond to the cholinesterase inhibitors, clinicians should consider quetiapine, clozapine, or olanzapine, keeping in mind that problematic orthostatism can occur with these agents. The mood-stabilizing effects of valproic acid or carbamazepine may be desired for some patients.

Depression is very common in DLB, likely due in part to the serotonergic dysfunction in this disorder. The SSRIs are usually effective and well tolerated. Although none of the newer antidepressant agents has been shown to be superior to the others, the tricyclic antidepressants should be avoided in DLB because of their anticholinergic properties. Electroconvulsive therapy can be effective in some patients without significantly worsening cognition. Anxiety is also common and can be treated by an SSRI or buspirone.

Motor Dysfunction

Many of the parkinsonian signs and symptoms of DLB can respond to carbidopa/levodopa and the dopamine agonists. Their use is limited by the side effects, as these agents can exacerbate psychotic symptoms or ortho-

statism. Since many DLB patients have a postural rather than resting tremor, therapies effective for essential/familial tremor can be used if the tremor significantly impedes activities of daily living. Electroconvulsive therapy may also alleviate parkinsonism through unknown mechanisms. Most experts view dementia as an exclusionary factor when considering surgical forms of therapy such as pallidotomy and deep-brain stimulation for parkinsonism.

Autonomic Dysfunction

Orthostatic hypotension can occur in DLB, likely due to degenerative changes in the intermediolateral cell column of the spinal cord (Pakiam et al, 1999). As in PD, management includes liberalizing salt in the diet, salt tablets, thigh-high compression stockings, fludrocortisone, and midodrine (Drugs to treat, 2002).

Sleep Disorders

Violent dreams/nightmares and potentially injurious dream enactment behavior are typical of RBD. However, patients with severe OSA can have features identical to RBD, and the nightmares and flailing limb behavior are eliminated with nasal CPAP. Hence, PSG +/- nasal CPAP trial should be considered in most DLB patients with a history suggesting RBD and/or OSA.

The goals of therapy for RBD are to minimize abnormal behavior and unpleasant dreams and, particularly, to minimize the potential for injury (Boeve et al, 2003a). All patients and their bed partners should be counseled on simple steps to minimize injury, such as moving lamps and nightstands away from the bed and placing a mattress or cushion of some type on the floor adjacent to the bed (many patients use inexpensive foam padding). Clonazepam has been the mainstay of medical therapy, usually effective at 0.25 mg/night to 0.50 mg/night, but

doses above 1 mg nightly are necessary in some patients (Olson et al, 2000; Schenck and Mahowald, 1990). Although there is reluctance to use agents such as clonazepam in patients with dementia, exacerbation of cognitive impairment is rarely seen in DLB patients with RBD when 0.25 mg to 1.0 mg of clonazepam is used (Boeve et al, 2003a; Boeve et al, 2001a). Recent experience with melatonin shows that doses ranging from 3 mg/night to 12 mg/night can be effective either as sole therapy, or in conjunction with clonazepam when either melatonin or clonazepam alone is ineffective (Boeve et al, 2003b). Other drugs reported to improve RBD include donepezil, triazolam (Olson et al, 2000), clozapine (Olson et al, 2000), and quetiapine (Boeve et al, 2003a; Boeve et al, 2001a).

Insomnia can be caused by degenerative changes in the key networks involved in the initiation and maintenance of sleep, by one or more primary sleep disorders (eg, restless legs syndrome, periodic limb movements in sleep, OSA, or central sleep apnea syndrome), by depression, and by medications (Boeve et al, 2001a). A careful sleep history and PSG can help determine the cause(s) and possible therapies (Boeve et al, 2001a). Contrary to popular belief, nasal CPAP therapy or bilevel positive airway pressure is tolerated by many patients with dementia, sometimes resulting in significant improvement in alertness and cognition (Boeve et al, 2001a). If due to cholinesterase inhibitor therapy, dosing donepezil in the morning or dosing rivastigmine or galantamine no later than 6:00 PM may alleviate insomnia. Drugs effective for primary insomnia include trazodone, melatonin, chloral hydrate, zolpidem, and the atypical neuroleptics (eg, quetiapine, olanzapine, clozapine, or risperidone). Among the SSRIs, fluoxetine may precipitate or aggravate insomnia, while mirtazepine may improve insomnia.

There are no published data or anecdotal reports regarding gamma-hydroxybutyrate, which has profound sedating effects.

Excessive daytime somnolence can be caused by a similar set of etiologies noted above for insomnia (Boeve et al, 2001a). Recent data in patients with PD and psychosis have shown narcoleptic-like features in some patients (Arnulf et al, 2000). Modafinil can improve excessive daytime somnolence in PD patients, and there are anecdotal reports of modafinil or methylphenidate improving hypersomnia in patients with DLB (Boeve et al, 2001a).

Although polysomnography can provide important diagnostic and therapeutic information, it can be arduous to perform in patients with DLB. Many sleep laboratories do not have simultaneous PSG video monitoring equipment, which is critical for evaluating patients with a parasomnia history. The slowing of the background EEG activity can make PSG scoring difficult. Non-neurologist sleep clinicians tend to focus on sleep-related breathing, although RBD and periodic limb movements in sleep are common in DLB. Therefore, DLB patients and their bed partners with sleep-related issues are often best served by referral to a sleep neurologist at an accredited sleep disorder center. Additional information on such neurologists and sleep disorder centers can be found by contacting the American Academy of Sleep Medicine (www.aasmnet.org).

CONTROVERSIES AND UNCERTAINTIES

Mild Cognitive Impairment Preceding Dementia With Lewy Bodies

MCI represents the transitional state between normal aging and dementia (Petersen et al, 2001; Petersen et al,

KEY POINTS:

- A All patients with RBD and their spouses should be counseled on measures to improve safety in the sleep environment. When the risk of injury due to RBD is a concern, clonazepam and/or melatonin is/are often effective and well tolerated.
- A Contrary to popular belief, nasal CPAP therapy or bilevel positive airway pressure is tolerated by many patients with dementia and OSA, sometimes resulting in significant improvement in alertness and cognition.
- A Insomnia due to cholinesterase inhibitor therapy can be managed by dosing donepezil in the morning or administering the second dose of rivastigmine or galantamine no later than the evening meal.

KEY POINTS:

- A Patients with DLB and their bed partners with sleep-related issues are often best served by referral to a sleep neurologist at an accredited sleep disorder center.
- A The qualitative and quantitative features of the MCI subtypes that evolve into DLB are still being defined.
- A Numerous genetic factors, most of which have not yet been identified, are likely associated with DLB and LBD.

1999). It is a pathologic state that presumably occurs in most if not all patients who eventually develop dementia on a degenerative basis, and thus individuals with AD, DLB, and frontotemporal dementia likely pass through an MCI state over months or years. Some have suggested a subclassification system for MCI, in which the cognitive characteristics (eg, amnesic MCI, single nonmemory domain MCI, and multiple domain MCI) and etiologic categories of disease (eg, degenerative, vascular, metabolic) can be presented, as in Figure 4-3 (Petersen et al, 2001). Most of the published data involves patients with amnesic MCI, which often evolves into AD. The other MCI subtypes are theoretical constructs, and the qualitative and quantitative features of the nonamnesic MCI subtypes and the prodromal states for the non-AD dementias are still being defined. As new therapies are developed that may affect amyloid, tau, and synuclein pathophysiology in the various dementing conditions, identification of the underlying disorder in patients with early symptoms, including MCI, will become increasingly important.

Other Conditions Preceding Dementia With Lewy Bodies

Data gathered thus far suggests that RBD, parkinsonism, orthostatic hypo-

tension, and MCI can each evolve into the full constellation of features characteristic of DLB (Case 4-3). It remains to be seen if other conditions, such as isolated visual hallucinations, anosmia, urinary incontinence, and other symptoms or disorders, can also represent the initial feature of evolving DLB (Figure 4-4).

Genetics of Dementia With Lewy Bodies

There are several reports of familial DLB (Brett et al, 2002; Galvin et al, 2002; Tsuang et al, 2002), and over half of the patients with probable DLB and RBD in one series had one or more first-degree relatives with parkinsonism or dementia (Boeve et al, 1998). Several of the cases in this chapter have a positive family history of parkinsonism or dementia, as well. Even within those families with DLB, there is significant clinical and neuropathologic heterogeneity (Brett et al, 2002; Galvin et al, 2002; Gwinn-Hardy, 2002; Tsuang et al, 2002). The DLB phenotype has been observed in at least one member of the Contursi kindred with a mutation in α -synuclein (Langston et al, 1998). Undoubtedly numerous genetic factors that are associated with DLB and LBD have not yet been identified.

Alzheimer's Disease Coexisting With Lewy Body Disease

Pathologic studies have shown that as many as 80% of cases with limbic or neocortical LBD have some degree of coexisting Alzheimer pathology, leading some to classify LBD into "pure" (no Alzheimer pathology) and "common" (sparse to frequent Alzheimer pathology) forms (Kosaka, 2000). Cases with common LBD tend to have diffuse +/- neuritic plaques but rather sparse to absent neurofibrillary tangles, particularly in the mesial temporal lobes, perhaps explaining why those

Subtype	Degenerative	Vascular	Metabolic	Other
Amnesic MCI	→ AD ? → DLB			
Single non memory domain MCI	? → AD ? → DLB ? → FTD			
Multiple-domain MCI	? → AD ? → DLB			

FIGURE 4-3 Subtypes and etiologic categories of mild cognitive impairment.

Case 4-3

A right-handed semiretired business executive exhibited no significant cognitive or motor symptoms until he was hospitalized at age 66 for pneumonia. He experienced confusion, temporal and geographic disorientation, and mild paranoia. Laboratory testing and CT of the head were unrevealing. A neurologist diagnosed AD despite the absence of symptoms prior to the hospitalization. Upon the patient's discharge to home, he returned to his neurologic baseline. Over the subsequent 6 months, he mistakenly wrote addresses on the wrong side of several envelopes and experienced one episode of geographic disorientation while driving. He was greatly concerned about these symptoms, fearing he was truly developing AD.

Over the preceding 5 years, he also had exhibited typical features of RBD but had neither injured himself nor his wife. His past medical history was otherwise unremarkable. Family history was notable for dementia in his mother, with onset in her sixties.

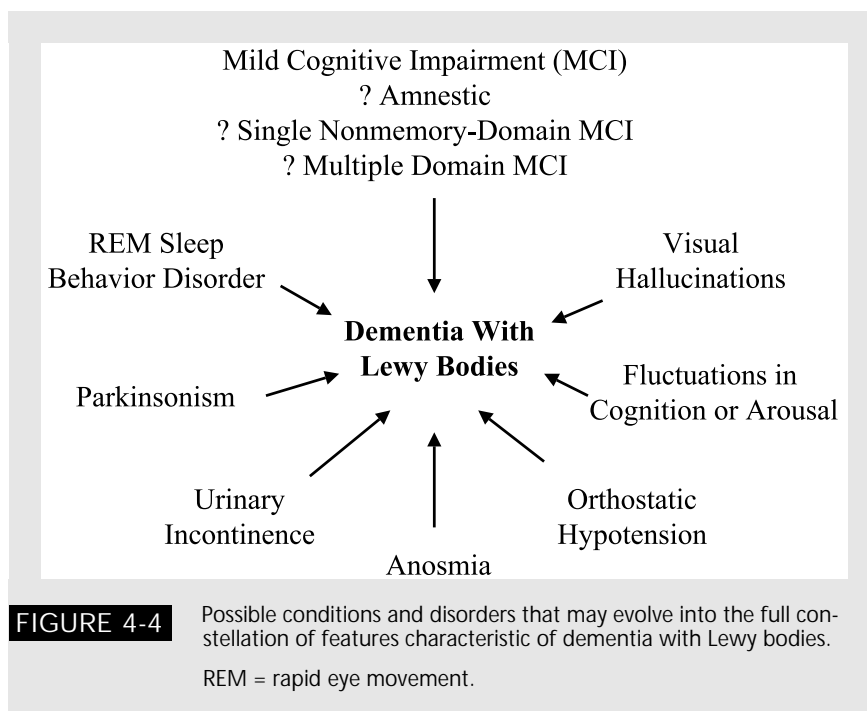
Neurologic examination showed a score of 33/38 on the Short Test of Mental Status, with difficulties particularly in construction, and a mild postural tremor. Neuropsychological testing was only notable for impairment in visuospatial/visuoconstructive abilities. Laboratory studies for reversible causes of cognitive impairment were normal. MRI showed mild generalized cerebral cortical atrophy but no hippocampal atrophy. Based on these findings and his retained functional abilities, the patient was diagnosed with MCI (single nonmemory domain) and was initiated on high-dose vitamin E.

Evaluations over the subsequent 3 years showed the evolution of multiple cognitive, neuropsychiatric, motor, sleep, and autonomic changes. By age 67 he was experiencing difficulties in reasoning and decision making as well as prominent fatigue. Neuropsychological testing again showed visuospatial/visuoconstructive difficulties, with the only new finding being impairment on executive functioning. He underwent PSG, which confirmed RBD but only mild positional OSA and few periodic limb movements during sleep. By age 68 he had developed orthostatic hypotension and impotence, and many of the cardinal features of PD had evolved. Yet he continued to be functionally independent, with only mild difficulties in problem solving and decision making. Neuropsychological testing showed impairment on attention/concentration in addition to those aforementioned in other nonmemory domains. By age 69 he was experiencing daily visual hallucinations involving children and animals, delusions of intruders in the home, prominent apathy, and striking fluctuations in arousal, yet his cognitive symptoms had not progressed much. Neuropsychological testing continued to show marked impairment in visuospatial functioning and attention/concentration, and while performance on delayed recall measures was dropping, his confrontation naming was almost perfect. By age 70 a suprapubic catheter had been placed to manage urinary incontinence, which improved his quality of life, but his functional abilities had declined greatly due to more prominent cognitive impairment and parkinsonism.

Comment. This patient presented with symptoms that caused him great concern but did not significantly affect activities of daily living. Clinical examination and neuropsychological testing showed impairment only in the visuospatial/visuoconstructive domain. Thus, his features at that time were consistent with nonamnestic MCI. Executive functions and attention/concentration were subsequently affected, and a dementia syndrome evolved, associated with the typical features of DLB. Some could argue that this case simply represents early cognitive deficiency associated with evolving PD, and dementia subsequently developed. In clinical practice such patients with worrisome symptoms but impairment in only one domain are often reassured that they do not have AD. The point here is that in some patients the concern is valid and indeed worrisome, as nonamnestic MCI can evolve into DLB.

KEY POINTS:

- A More work is needed to clarify the clinical and pathophysiologic significance of Alzheimer pathology associated with Lewy body disease.
- A Controversy continues as to whether patients with DLB and PDD represent one or more distinct pathophysiologic processes, differing primarily in the time course of when the various features became manifest. Data gathered thus far suggest more similarities than differences.



with coexisting AD pathology still have relatively preserved memory functioning. Even those with autosomal dominant AD associated with mutations in presenilin 1, presenilin 2, or amyloid precursor protein, as well as patients with Down's syndrome, can have some degree of LBD pathology (Lippa et al, 1995; Trembath et al, 2003). Some authorities view cases with AD and LBD pathology not as two distinct pathophysiologic processes but as related processes; this view has fostered the term Lewy body variant of Alzheimer's disease (Hansen and Samuel, 1997), although it has been disputed (Dickson, 1990). Clearly, more work is needed to clarify the clinical and pathophysiologic significance of Alzheimer pathology associated with Lewy body disease.

Dementia With Lewy Bodies and Parkinson's Disease With Dementia

Controversy continues as to whether patients with typical features of PD who subsequently develop dementia

(ie, PDD) have the same underlying pathophysiologic process as do patients with dementia, fluctuations, and visual hallucinations who subsequently develop parkinsonism (ie, DLB), differing primarily in the time course of when the various features became manifest (McKeith, 2000; Richard et al, 2002). Recent evidence suggests that brain stem, limbic, +/- neocortical Lewy bodies and Lewy neurites characteristic of Lewy body disease are the common thread that ties PDD and DLB together (Apaydin et al, 2002; Dickson, 2002). Neuropathologists are not able to predict which clinical phenotype was exhibited antemortem in those with LBD (Dickson, 2001; Dickson, 2002). Furthermore, one can argue that the management of PDD is very similar, if not identical, to that of DLB. The available data therefore suggest that from the clinical, pathologic, and pathophysiologic perspectives, DLB and PDD are far more similar than different, but some authorities still contend that the two should be considered as separate entities (Richard et al, 2002).

REFERENCES

- " Aarsland D, Ballard C, Larsen JP, McKeith I. A comparative study of psychiatric symptoms in dementia with Lewy bodies and Parkinson's disease with and without dementia. *Internat J Geriatr Psychiatry* 2001; 16:528–536.
- This study showed clinical differences among dementia with Lewy bodies (DLB), Parkinson's disease (PD), and Parkinson's disease with dementia (PDD).
- " Aarsland D, Larsen JP, Lim NG, Tangberg E. Olanzapine for psychosis in patients with Parkinson's disease with and without dementia. *J Neuropsychiatry Clin Neurosci* 1999;11:392–394.
- This small study showed that olanzapine improved psychotic symptoms in patients with PD +/- dementia.
- " Ala TA, Hughes LF, Kyrouac GA, et al. Pentagon copying is more impaired in dementia with Lewy bodies than in Alzheimer's disease. *J Neurol Neurosurg Psychiatry* 2001;70:483–488.
- This study by Ala and colleagues demonstrated that poor construction may help differentiate DLB from Alzheimer's disease (AD).
- " Apaydin H, Ahlskog J, Parisi J, et al. Parkinson's disease neuropathology: later-developing dementia and loss of the levodopa response. *Arch Neurol* 2002;59:102–112.
- This study showed that limbic and neocortical Lewy bodies were associated with dementia and loss of levodopa response in patients who had classic PD features for at least 4 years.
- " Arnulf I, Bonnet AM, Damier P, et al. Hallucinations, REM sleep, and Parkinson's disease: a medical hypothesis. *Neurology* 2000;55:281–288.
- This was the first study to suggest that some of the features of patients with PD and DLB could represent "narcoleptic-like" phenomena.
- " Ballard C, Holmes C, McKeith I, et al. Psychiatric morbidity in dementia with Lewy bodies: a prospective clinical and neuropathological comparative study with Alzheimer's disease. *Amer J Psychiatry* 1999;156:1039–1045.
- " Ballard C, O'Brien J, Gray A, et al. Attention and fluctuating attention in patients with dementia with Lewy bodies and Alzheimer disease. *Arch Neurol* 2001;58:977–982.
- " Ballard C, Shaw F, McKeith I, et al. High prevalence of neurovascular instability in neurodegenerative dementias. *Neurology* 1998;51:1760–1762.
- This series of studies by Ballard and colleagues attempts to characterize fluctuations, psychiatric features, and morbidity in DLB.
- " Barber R, Ballard C, McKeith IG, et al. MRI volumetric study of dementia with Lewy bodies: a comparison with AD and vascular dementia. *Neurology* 2000;54:1304–1309.
- " Barber R, Gholkar A, Scheltens P, et al. Medial temporal lobe atrophy on MRI in dementia with Lewy bodies. *Neurology* 1999;52:1153–1158.
- The above studies by Barber and colleagues demonstrate less temporal lobe atrophy in DLB compared with AD.

- " Boeve B, Silber M, Ferman T, et al. REM sleep behavior disorder in Parkinson's disease, dementia with Lewy bodies, and multiple system atrophy. In: Bedard M, Agid Y, Chouinard S, et al, eds. *Mental and behavioral dysfunction in movement disorders*. Totowa, NJ: Humana Press, 2003a:383–397.

The chapter summarizes many issues relating to rapid eye movement (REM) sleep behavior disorder (RBD) and the synucleinopathies.

- " Boeve B, Silber M, Ferman T. Melatonin for treatment of REM sleep behavior disorder in neurologic disorders: Results in 14 patients. *Sleep Med* 2003b; 4:281–284.

This open-label study shows that melatonin can be effective as sole or add-on therapy for RBD associated with neurologic disorders.

- " Boeve B, Silber M, Ferman T. Current management of sleep disturbances in dementia. *Cur Neurol Neurosci Rep* 2001a;2:169–177.

This review summarizes an approach to manage sleep disturbances in dementia.

- " Boeve B, Silber M, Ferman T, et al. Association of REM sleep behavior disorder and neurodegenerative disease may reflect an underlying synucleinopathy. *Mov Disord* 2001b;16:622–630.

This analysis of several sets of data suggests that RBD associated with neurodegenerative disease may reflect an underlying synucleinopathy.

- " Boeve B, Silber M, Parisi J, et al. Synucleinopathy pathology and REM sleep behavior disorder plus dementia or parkinsonism. *Neurology* 2003c; 61:40–45.

This clinicopathologic analysis showed that all 15 patients with RBD plus dementia or parkinsonism had either Lewy body disease (LBD) or multiple system atrophy.

- " Boeve BF, Silber MH, Ferman TJ, et al. REM sleep behavior disorder and degenerative dementia: an association likely reflecting Lewy body disease. *Neurology* 1998;51:363–370.

This was the first report to suggest an association between RBD and DLB.

- " Brett FM, Henson C, Staunton H. Familial diffuse Lewy body disease, eye movement abnormalities, and distribution of pathology. *Arch Neurol* 2002;59:464–467.

Supranuclear gaze palsy was seen in some of the affected members of familial diffuse LBD.

- " Briel RC, McKeith IG, Barker WA, et al. EEG findings in dementia with Lewy bodies and Alzheimer's disease. *J Neurol Neurosurg Psychiatry* 1999;66:401–403.

This study showed that there was greater electroencephalogram slowing in DLB compared with AD patients.

- " Cummings JL, Street J, Masterman D, Clark WS. Efficacy of olanzapine in the treatment of psychosis in dementia with lewy bodies. *Dement Geriatr Cog Disord* 2002;13:67–73.

This study showed olanzapine was effective at improving psychosis in DLB.

- " DeI Ser T, McKeith I, Anand R, et al. Dementia with lewy bodies: findings from an international multicentre study. *Int J Geriatr Psychiatry* 2000;15: 1034–1045.
Several nontreatment aspects of this multicenter study with rivastigmine for treatment of DLB are detailed in this paper.
- " Dewey RJ, O’Suilleabhain P. Treatment of drug-induced psychosis with quetiapine and clozapine in Parkinson’s disease. *Neurology* 2000;55: 1753–1754.
These investigators report efficacy of quetiapine and clozapine for treatment of drug-induced psychosis in PD.
- " Dickson DW. Dementia with Lewy bodies: neuropathology. *J Geriatr Psychiatry Neurol* 2002;15:210–216.
- " Dickson DW. Alpha-synuclein and the Lewy body disorders. *Curr Opin Neurol* 2001;14:423–432.
These papers by Dickson are excellent reviews of DLB neuropathology.
- " Dickson DW. Lewy body variant. *Neurology* 1990;40:1147–1150.
This author provides an argument against the concept and use of the term “Lewy body variant of AD.”
- " Drugs to treat autonomic dysfunction in Parkinson’s disease. *Mov Disord* 2002;17(suppl 4):S103–S111.
Excellent review of the drugs available in the United States and abroad that can treat autonomic dysfunction in PD.
- " Ferman T, Boeve B, Smith G, et al. Dementia with Lewy bodies may present as dementia with REM sleep behavior disorder without parkinsonism or hallucinations. *J Int Neuropsychol Soc* 2002;8:907–914.
This study showed that the neuropsychological profile of impairment in patients with dementia and RBD but without hallucinations or parkinsonism was indistinguishable from patients with DLB but different from patients with autopsy-confirmed AD.
- " Ferman TJ, Boeve BF, Smith GE, et al. REM sleep behavior disorder and dementia: cognitive differences when compared with AD. *Neurology* 1999;52: 951–957.
This was the first study to demonstrate cognitive differences between patients with RBD/dementia (probable DLB) and autopsy-confirmed AD.
- " Folstein M, Folstein S, McHugh P. “Mini-mental state”. A practical method for grading the cognitive state of patients for the clinician. *J Psychiatry Res* 1975;12:189–198.
This is the original reference for the Mini-Mental Status Examination.
- " Galasko D. Lewy bodies and dementia. *Curr Neurol Neurosci Rep* 2001;1: 435–441.
This is an excellent review on DLB by a noted expert in this disorder.
- " Galvin JE, Lee SL, Perry A, et al. Familial dementia with Lewy bodies: clinicopathologic analysis of two kindreds. *Neurology* 2002;59:1079–1082.
These authors describe two small kindreds with familial DLB.

- " Gwinn-Hardy K. Genetics of parkinsonism. *Mov Disord* 2002;17:645–656.
This is an up-to-date review of the genetics of parkinsonism.
- " Hansen L, Samuel W. Criteria for Alzheimer's disease and the nosology of dementia with Lewy bodies. *Neurology* 1997;48:126–132.
This paper by Hansen et al reviews some of the issues regarding the relationship of AD and DLB.
- " Hishikawa N, Hashizume Y, Yoshida M, Sobue G. Clinical and neuropathological correlates of Lewy body disease. *Acta Neuropathol* 2003;105:341–350.
This clinicopathologic study suggested that DLB, PD with and without dementia, and pure autonomic failure share one clinicopathologic entity.
- " Hohl U, Tiraboschi P, Hansen L, et al. Diagnostic accuracy of dementia with Lewy bodies. *Arch Neurol* 2000;57:347–351.
This study showed that early spontaneous extrapyramidal signs in AD were associated with false-positive diagnoses of DLB.
- " Jack CR Jr, Petersen RC, Xu Y, et al. Rates of hippocampal atrophy correlate with change in clinical status in aging and AD. *Neurology* 2000;55:484–489.
- " Jack CR Jr, Petersen RC, Xu YC, et al. Prediction of AD with MRI-based hippocampal volume in mild cognitive impairment. *Neurology* 1999;52:1397–1403.
These papers by Jack and colleagues demonstrate the association and predictive value of hippocampal atrophy in mild cognitive impairment (MCI) and AD.
- " Johns M. A new method for measuring daytime sleepiness: the Epworth sleepiness scale. *Sleep* 1991;14:540–545.
This is the original reference for the Epworth Sleepiness Scale, which is now being used in DLB research.
- " Knopman DS, Boeve BF, Petersen RC. Essentials of the proper diagnosis of mild cognitive impairment, dementia, and major subtypes of dementia. *Mayo Clin Proc* 2003;78:1290–1308.
- " Knopman DS, DeKosky ST, Cummings JL, et al. Practice parameter: diagnosis of dementia (an evidence-based review). Report of the Quality Standards Subcommittee of the American Academy of Neurology. *Neurology* 2001;56:1143–1153.
This is the AAN practice parameter for the diagnosis of dementia, which is reprinted in this issue as Appendix B.
- " Kokmen E, Smith G, Petersen R, et al. The short test of mental status: correlations with standardized psychometric testing. *Arch Neurol* 1991;48:725–728.
These two papers by Kokmen and colleagues present data regarding the utility of the Short Test of Mental Status in assessing cognitive impairment.
- " Kosaka K. Diffuse Lewy body disease. *Neuropathology* 2000;20:S73–S78.
This is an excellent review by one of the original investigators in the neuropathologic characterization of LBD.

" Lanctot KL, Herrmann N. Donepezil for behavioural disorders associated with Lewy bodies: a case series. *Internat J Geriatr Psychiatry* 2000;15: 338–345.

This case series touts the efficacy of donepezil for treatment of DLB.

" Langston J, Sastry S, Chan P, et al. Novel a-synuclein-immunoreactive proteins in brain samples from the Contursi kindred, Parkinson's, and Alzheimer's disease. *Exp Neurol* 1998;154:684–690.

This study involves a patient with the DLB phenotype associated with an α -synuclein mutation.

" Leopold NA. Risperidone treatment of drug-related psychosis in patients with parkinsonism. *Mov Disord* 2000;15:301–304.

This study shows that risperidone can be effective for hallucinations in patients with parkinsonism.

" Lippa C, Smith T, Nee L, et al. Familial Alzheimer's disease and cortical Lewy bodies: is there a genetic susceptibility factor. *Dementia* 1995;6: 191–194.

This paper poses questions involving the relationship of Lewy bodies in familial AD.

" Lobotesis K, Fenwick JD, Phipps A, et al. Occipital hypoperfusion on SPECT in dementia with Lewy bodies but not AD. *Neurology* 2001;56: 643–649.

This study suggests that occipital hypoperfusion on single-photon emission computed tomography may predict underlying DLB.

" Lopez O, Hamilton R, Becker J, et al. Severity of cognitive impairment and the clinical diagnosis of AD with Lewy bodies. *Neurology* 2000;54: 1780–1787.

These investigators did not find the current DLB diagnostic criteria to be predictive of DLB regardless of the severity of the dementia.

" Mahowald M, Schenck C. REM sleep behavior disorder. In: Kryger M, Roth T, Dement W, eds. *Principles and practice of sleep medicine*. Philadelphia: WB Saunders, 2000:724–741.

This chapter presents a comprehensive review of RBD written by the original investigators who characterized RBD.

" Marantz AG, Verghese J. Capgras' syndrome in dementia with Lewy bodies. *J Geriatr Psychiatry Neurol* 2002;15:239–241.

This paper describes one case in detail and a retrospective chart review regarding Capgras' syndrome in DLB.

" McKeith I, Del Ser T, Spano P, et al. Efficacy of rivastigmine in dementia with Lewy bodies: a randomised, double-blind, placebo-controlled international study. *Lancet* 2000a;356:2031–2036.

This is the largest controlled study of any agent for DLB, which demonstrated the efficacy of rivastigmine for cognitive and neuropsychiatric symptoms in this disorder.

" McKeith IG. Spectrum of Parkinson's disease, Parkinson's dementia, and Lewy body dementia. *Neurol Clin* 2000;18:865–902.

This paper reviews the similarities and differences between PD, PDD, and DLB.

- " McKeith IG, Ballard CG, Perry RH, et al. Prospective validation of consensus criteria for the diagnosis of dementia with Lewy bodies. *Neurology* 2000b;54:1050–1058.

This study by the Newcastle group showed reasonable sensitivity and specificity for the diagnosis of DLB.

- " McKeith IG, Burn DJ, Ballard CG, et al. Dementia with Lewy bodies. *Sem Clin Neuropsychiatry* 2003;8:46–57.

This is an excellent up-to-date review of DLB.

- " McKeith IG, Galasko D, Kosaka K, et al. Consensus guidelines for the clinical and pathologic diagnosis of dementia with Lewy bodies (DLB): report of the consortium on DLB international workshop. *Neurology* 1996;47:1113–1124.

This seminal paper on DLB characterization, describes the clinical ("McKeith") criteria and pathologic criteria for the diagnosis of DLB.

- " McKeith IG, Perry EK, Perry RH. Report of the second dementia with Lewy body international workshop: diagnosis and treatment. *Consortium on Dementia with Lewy Bodies. Neurology* 1999;53:902–905.

This report summarizes the rather minimal changes in the diagnosis and treatment of DLB as recommended by the second international workshop on DLB.

- " Mega M, Masterman D, Benson D, et al. Dementia with Lewy bodies: reliability and validity of clinical and pathologic criteria. *Neurology* 1996;47:1403–1409.

This study was one of the first validation studies on the DLB criteria, which emphasized the need for refined criteria as sensitivity and specificity were below 80%.

- " Minoshima S, Foster NL, Sima AA, et al. Alzheimer's disease versus dementia with Lewy bodies: cerebral metabolic distinction with autopsy confirmation. *Ann Neurol* 2001;50:358–365.

This study by Minoshima and colleagues suggests that occipital hypometabolism may be predictive of underlying DLB.

- " Mirra S, Gearing M, Heyman A. CERAD guide to the clinical assessment of Alzheimer's disease and other dementias. CERAD, 1994.

This guide describes the methodology and characterization of AD, DLB, and other dementias as suggested by the Consortium to Establish a Registry in Alzheimer's Disease (CERAD).

- " Mori E, Shimomura T, Fujimori M, et al. Visuo-perceptual impairment in dementia with Lewy bodies. *Arch Neurol* 2000;57:489–493.

This was the most comprehensive study to date to characterize the visuo-perceptual impairment in DLB.

- " Okazaki H, Lipkin L, Aronson S. Diffuse intracytoplasmic ganglionic inclusions (Lewy type) associated with progressive dementia and quadriplegia in flexion. *J Neuropathol Exp Neurol* 1961;20:237–244.

This is the first report on extranigral Lewy bodies associated with dementia.

- " Olson E, Boeve B, Silber M. Rapid eye movement sleep behavior disorder: demographic, clinical, and laboratory findings in 93 cases. *Brain* 2000;123:331–339.
This paper reports the findings in 93 consecutive patients with RBD at one institution, many of whom had coexisting dementia.
- " Osterrieth P. Le test de copie d'une figure complexe. *Arch Psychol* 1944;30:206–356.
This is the original reference for the Rey-Osterrieth Complex Figure Test, which is often used to demonstrate the profound visuoconstructive deficit in patients with DLB.
- " Pakiam AS, Bergeron C, Lang AE. Diffuse Lewy body disease presenting as multiple system atrophy. *Can J Neurol Sci* 1999;26:127–131.
This is one of the first reports on the prominent autonomic dysfunction in a patient with LBD.
- " Petersen R, Doody R, Kurz A, et al. Current concepts in mild cognitive impairment. *Arch Neurol* 2001;58:1985–1992.
- " Petersen R, Smith G, Waring S, et al. Mild cognitive impairment: Clinical characterization and outcome. *Arch Neurol* 1999;56:303–308.
These papers by Petersen and colleagues describe the current concepts, characterization, and outcome in patients with MCI.
- " Richard IH, Papka M, Rubio A, et al. Parkinson's disease and dementia with Lewy bodies: one disease or two? *Mov Disord* 2002;17:1161–1165.
This paper summarizes the relationship between PDD and DLB.
- " Salmon D, Galasko D, Hansen L, et al. Neuropsychological deficits associated with diffuse Lewy body disease. *Brain Cogn* 1996;31:148–164.
This is the first detailed report on the neuropsychological deficits associated with DLB.
- " Schenck C, Mahowald M. REM sleep behavior disorder: Clinical, developmental, and neuroscience perspectives 16 years after its formal identification in SLEEP. *Sleep* 2002;25:120–138.
This is a superb up-to-date review on many aspects of RBD phenomenology, including the relationship of RBD to DLB.
- " Schenck C, Mahowald M. A polysomnographic, neurologic, psychiatric and clinical outcome report on 70 consecutive cases with REM sleep behavior disorder (RBD): sustained clonazepam efficacy in 89.5% of 57 treated patients. *Clev Clin J Med* 1990;57(suppl):10–24.
This case series suggests that clonazepam is effective in the vast majority of patients with RBD.
- " Simard M, van Reekum R, Cohen T. A review of the cognitive and behavioral symptoms in dementia with Lewy bodies. *J Neuropsychiatry Clin Neurosci* 2000;12:425–450.
This is an excellent review of the cognitive and behavioral symptoms in DLB.
- " Spillantini M, Crowther R, Jakes R, et al. Filamentous alpha-synuclein inclusions link multiple system atrophy with Parkinson's disease and dementia with Lewy bodies. *Neurosci Lett* 1998;251:205–208.
This is one of the first reports to suggest that multiple system atrophy, PD, and DLB are synucleinopathies.

- " Tariot PN, Ismail MS. Use of quetiapine in elderly patients. *J Clin Psychiatry* 2002;63:21–26.
These authors review the use of quetiapine in older adult patients.
- " Trembath Y, Rosenberg C, Ervin JF, et al. Lewy body pathology is a frequent co-pathology in familial Alzheimer's disease. *Acta Neuropathol* 2003;105:484–488.
This is another report regarding Lewy body pathology in familial AD.
- " Tsuang DW, Dalan AM, Eugenio CJ, et al. Familial dementia with Lewy bodies: a clinical and neuropathological study of 2 families. *Arch Neurol* 2002;59:1622–1630.
This is another report on familial DLB.
- " Turner RS, Chervin RD, Frey KA, et al. Probable diffuse Lewy body disease presenting as REM sleep behavior disorder. *Neurology* 1997;49:523–527.
This case report involves a patient with typical DLB clinical findings who initially presented with RBD.
- " Verghese J, Crystal HA, Dickson DW, Lipton RB. Validity of clinical criteria for the diagnosis of dementia with Lewy bodies. *Neurology* 1999;53:1974–1982.
These investigators found high negative predictive value and moderate positive predictive value using the consensus criteria for the clinical diagnosis of DLB.
- " Walker MP, Ayre GA, Cummings JL, et al. The Clinician Assessment of Fluctuation and the One Day Fluctuation Assessment Scale. Two methods to assess fluctuating confusion in dementia. *Brit J Psychiatry* 2000a;177:252–256.
- " Walker MP, Ayre GA, Perry EK, et al. Quantification and characterization of fluctuating cognition in dementia with Lewy bodies and Alzheimer's disease. *Dem Geriatr Cog Disord* 2000b;11:327–335.
These papers by Walker and colleagues describe methodologies for characterizing fluctuations in DLB.
- " Walker Z, Grace J, Overshot R, et al. Olanzapine in dementia with Lewy bodies: a clinical study. *Int J Geriatr Psychiatry* 1999;14:459–466.
In this small study, the majority of DLB patients either did not tolerate or failed to improve with olanzapine.